



PATIENT

Carley Champagne

SPECIES

Canine

BREED

Jack Russell Terrier
Mix

SEX

Female Spayed

AGE

15 years

WEIGHT

31.9lbs

INTERPRETED BY

Maggie Machen
Lamy, DVM, DACVIM
(Cardiology)

IMAGING PERFORMED BY

Jenna Walsh, CVT

HOSPITAL NAME

Willamette Veterinary
Hospital

REFERRING VET

Dr. Cohen/Maggiulli

INVOICE

23512

DATE

4/7/22

PRESENTING CLINICAL SIGNS

History: Presented for hindlimb collapse/ataxia. Panting with increased RE. Chronic intermittent cough.
 -Current medications: Pimobendan- 2.5 mg 2 caps q12h, Sildenafil 20 mg - 1 tablet q8 -only has had 2 doses before echo.

-Radiology report: Patchy, predominately caudodorsal pulmonary infiltrate, mild right heart enlargement. Suspect early PAH.

-Abnormal PE/Chem/CBC/UA Results: CBC = HCT 44%, mild leukocytosis 18.68k, mild neutrophilia 15.85k, mild monocytosis 1.27, stress leukogram, thrombocytosis 586k Chem17 = phosph 7.2, ALP 1842, Cholesterol 379 lytes = all wnl. K 4.5 4Dx- Negative x4.

ELECTROCARDIOGRAPHIC FINDINGS *Note: Single lead ECGs are evaluated as a rhythm strip. Morphology/MEA cannot be definitively commented on.

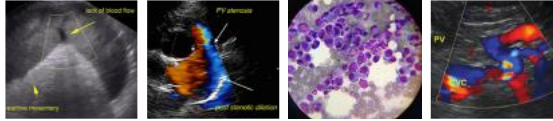
A single lead ECG is available; 50mm/s, 20mm/mV. The average heart rate is 160bpm with a largely regular rhythm. P waves are difficult to identify throughout; however, a sinus origin is suspected. The QRS is isoelectric. No premature beats, pauses or other dysrhythmias observed. ECG diagnosis: Normal sinus rhythm.

ECHOCARDIOGRAM FINDINGS

2D, m-mode, color flow and doppler imaging is available. Mild diffuse thickening of mitral valve leaflets with no prolapse into the left atrial lumen. Mild anterior-directed mitral regurgitation with mild left atrial dilation. Normal MR velocity. Decreased LV diameter with adequate myocardial function. The LV wall thickness is increased globally. Hyperechoic endocardium consistent with fibrosis. The tricuspid valve appears mildly thickened with mild tricuspid regurgitation. Prominent right heart. TR velocity indicative of early pulmonary arterial hypertension. The pulmonic and aortic valves are normal in morphology and mobility. Normal pulmonic and aortic outflow velocities with laminar flow. Mild aortic and no pulmonic insufficiency. No pericardial or pleural effusion noted. No obvious cardiac masses.

CARDIAC CHART

CANINE CARDIAC PARAMETERS	MR VMAX (m/s)	TR VMAX (m/s)	LA/AO (Boon method)	LA/AO (Heart Base; Swe)	FS (%)	EF (%)	EPSS (cm)
NORMAL PARAMETER	4.5-5.5	<2.7	1.3	<1.6	28-40	40-100	<0.6
PATIENT	5.9	2.9	1.3	1.4			NM
CANINE CARDIAC PARAMETERS	HR (BPM)	AV VMAX (m/s)	PV MAX (m/s)	BODY WEIGHT (kg)	LA 2D short axis Base view (cm)	LVIDd Avg; 2D and m-mode short axis (cm)	LVIDs Avg; 2D and m-mode short axis (cm)
NORMAL PARAMETER	50-100	0.7-1.7	0.7-1.6	BELOW	BELOW	BELOW	BELOW
PATIENT	140		1.5	14.5	2.0		
*Normal chamber parameters expressed as a mean value (SD)				3	1.27 (5.3)	2.46 (2.46)	1.36 (5.5)
BODY WEIGHT DEPENDENT PARAMETERS				5	1.40 (4.5)	2.74 (5.2)	1.60 (4.7)
				10	1.50 (3.8)	3.27 (3.5)	2.06 (3.1)



PATIENT

Carley Champagne

SPECIES

Canine

BREED

Jack Russell Terrier
Mix

SEX

Female Spayed

AGE

15 years

WEIGHT

31.9lbs

INTERPRETED BY

Maggie Machen
Lamy, DVM, DACVIM
(Cardiology)

IMAGING PERFORMED BY

Jenna Walsh, CVT

HOSPITAL NAME

Willamette Veterinary
Hospital

REFERRING VET

Dr. Cohen/Maggiulli

INVOICE

23512

DATE

4/7/22

Adapted from June Boon, Veterinary Echocardiography, 1998 Rishniw M and Hollis NE, J Vet Intern Med 2000; 14:429-435 Hansson et al, Vet Rad and Ultrasound 2002 Bonagura et al. Echocardiography: principles of interpretation, Vet Clin North Am 15:1177, 1995	15	1.83 (2.0)	3.71 (2.4)	2.43 (2.1)
	20	2.02 (1.9)	4.14 (2.2)	2.80 (2.0)
	25	2.18 (2.4)	4.48 (2.9)	3.10 (2.5)
	30	2.33 (3.3)	4.83 (3.9)	3.39 (3.4)
	35	2.48 (4.3)	5.17 (5.0)	3.69 (4.5)
	40	2.62 (5.2)	5.48 (6.1)	3.96 (5.4)
	50	2.88 (7.1)	6.07 (8.3)	4.46 (7.4)

INTERPRETATION OF THE FINDINGS & FURTHER RECOMMENDATIONS

Chronic degenerative valve disease causing mild mitral and tricuspid regurgitation. Lack of significant left atrial enlargement indicates the current risk for complication is low. Mild pulmonary hypertension is noted, which is likely developing secondary to the airway disease. Finally an aortic leak is noted with significant LV hypertrophy, both which likely **suggest systemic hypertension and a baseline blood pressure is strongly recommended.** No additional issues are noted in this study. The ECG is unremarkable with a normal sinus rhythm.

Given these findings, the **respiratory signs are certainly non-cardiogenic in origin.** Primary respiratory disease is considered most likely, based upon the radiograph report, signalment and findings here. If the signs are poorly controlled/progresses long term, this can certainly lead to worsening of PAH. Clinical signs of significant PAH include exertional dyspnea/collapse. Continued monitoring is advised. Sildenafil is not clearly warranted at this time. That being said, if the patient had significant clinical improvement once the medication was started, it is of little negative consequence to continue. Pimobendan is not yet indicated in this case.

Assessment of progression in the future will help predict long term prognosis, which is highly variable at this stage (B1). Omega fatty acid supplementation and mild salt restriction may be of some long-term benefit. Monitor for development of a cough, labored breathing, exercise intolerance or collapse episodes.

Anesthetic risk is considered mild if needed. Cardiac protective drug choices (opioid/benzodiazepine premedication, propofol or alfaxalone induction, isoflurane gas) are recommended. **Pre-oxygenate for 5-10 minutes prior to induction.** Monitor for arrhythmias, hypotension, and hypoxia both intra and post-operatively and intervene as necessary. Mild IV fluid restriction is recommended to avoid fluid overload. Avoid heart rate stimulating drugs such as atropine unless clinically indicated.

PLAN

Discontinue Pimobendan. If significant improvement was noted on Sildenafil, reasonable to continue; otherwise discontinue as well. Baseline BP strongly recommended, particularly in light of presenting hindlimb weakness. Institute Amlodipine if BP is significantly elevated and screen for underlying causes, such as an adrenal tumor. Further respiratory treatment/evaluation as dictated by the clinical picture.

Recommend conservative monitoring with a recheck echocardiogram in 6 months, sooner if any development of clinical signs.



PATIENT

Carley Champagne

SPECIES

Canine

BREED

Jack Russell Terrier
Mix

SEX

Female Spayed

AGE

15 years

WEIGHT

31.9lbs

INTERPRETED BY

Maggie Machen
Lamy, DVM, DACVIM
(Cardiology)

IMAGING PERFORMED BY

Jenna Walsh, CVT

HOSPITAL NAME

Willamette Veterinary
Hospital

REFERRING VET

Dr. Cohen/Maggiulli

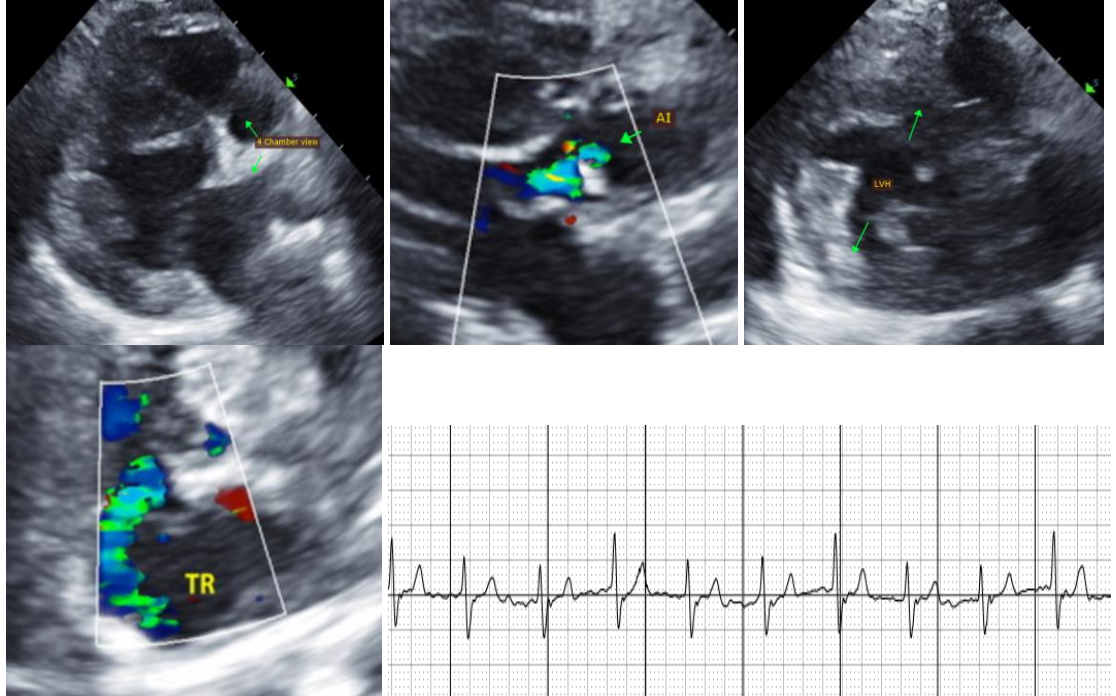
INVOICE

23512

DATE

4/7/22

IMAGES



The information and recommendations provided are based on the images presented by the referring veterinarian. No evaluation can be communicated regarding pathology that was not visible in the image/video clips provided.

Thank you for this referral. This report was generated using transcription software, and minor dictation errors may be present. If the clinical or image interpretation does not parallel your findings or if I can be of any further assistance, please contact me.

Maggie Machen Lamy, DVM
Diplomate of the American College of Veterinary Internal Medicine (Cardiology)
info@sonopath.com